

## Guided Maxillary Full-Arch Implant-Supported Rehabilitation with Immediate Loading Using All-On-6 Concept: A Case Report

**Fedir Shchepanskyi** (PhD in Medical Sciences, Head of the Department of Prosthodontics, Lviv Medical University, Ukraine)

**Borys Shchepanskyi** (PhD in Medical Sciences, Assistant of the Department of Prosthodontics, Lviv Medical University, Public organization “DentOnline Study Club”, Ukraine)

\*Corresponding author: Borys Shchepanskyi

Received: October 01, 2023

Published: November 02, 2023

**Abstract.** The quality of life of each person affects activities, ability to work and its harmonious development. One of the elements related to the quality of life is the level of health of the oral cavity and teeth. Periodontal diseases are among the most common non-infectious diseases. Implant-supported fixed prosthesis is the best option available to patients for the rehabilitation of edentulous jaws. Immediate loading of a fixed prosthesis significantly improves the quality of life of patients during osseointegration period of implants. The use of immediate loading of fixed prostheses has demonstrated clinical

efficacy that extends to oral health-related quality of life and patient satisfaction. This article presents a clinical example of rehabilitation of the maxillary arch. The same day simultaneous guided implants placement with immediate provisional loading by a fixed screw-retained implant supported prosthesis is justified. Successful treatment outcome requires correct diagnostics and accurate treatment planning.

**Keywords:** dental implant, immediate loading, ALL-ON-6, surgical guide, CAD/CAM, intraoral welding.

**Introduction.** The quality of life of each person affects daily comfort, activities, ability to work and their harmonious development. It allows to live to a ripe old age, maintain moral, mental, and physical health. One of the elements of the quality of life is the level of health of the oral cavity and teeth. The efficiency of grinding food during nutrition ensures the daily needs of a person in substances that are not produced by the organism. Proteins, vitamins, fats, mineral elements, and dietary fibers enter the body only with food. Rational nutrition ensures proper growth and formation of the body, contributes to effective health support, a high level of work capacity and communication with people.

According to research by experts of the World Health Organization, diseases of the oral cavity affect almost 3.5 billion people. Untreated caries (tooth decay) of permanent teeth, severe periodontal diseases are among the most common non-infectious diseases affecting the population of all age groups throughout the life. They cause pain and suffering, discomfort and the development of accompanying health disorders, lead to injuries, disability, and fatalities [1].

Severe periodontal diseases have been steadily increasing over the past three decades, which is the 12<sup>th</sup> most common pathology in the world [2,3].

Partial adentia affects almost 70% of the population of Ukraine. Of which 9.3% are associated with complete loss of teeth in the adult population. There is a high need for modern dental care during the rehabilitation of affected dentitions [4].

At the same time, taking into account the age of the person, 42.2% of the population need complete removable prosthodontics. The need for dental care increases with age [5]:

- at the age of 60-69 years, total edentulism is observed in 9.9% of cases;
- at the age of 70-79 – 29.0%;
- over 80-89 years old – 20.2%;
- in patients over 90 years old – in 78.4% of cases.

Modern treatment of the oral cavity is based on the leading method of treatment of the total tooth loss – the production of complete removable prostheses. However, its effectiveness is

insufficient because 20-26% of patients with complete total edentulism do not use manufactured dentures due to poor fixation and stabilization [6,7].

Screw-retained and cemented fixed implant prostheses have proven themselves well as a method of treatment for patients with edentulous jaws. Clinical studies show that this type of restorations can be successful in the long term [8-12].

It happened that the rehabilitation of patients with complete loss of teeth could be carried out only with the help of traditional methods of orthopedic treatment using dentures and prostheses on subperiosteal implants [13]. Due to complications when using subperiosteal implants (mobility, questionable survival, service life of 5-7 years), a denture remains the main method of choice for the treatment of complete total edentulism.

Given the widespread use of dental implants for edentulous jaw conditions treatment, the treatment of patients with total tooth loss with implant-supported prostheses has become quite common. Restoration of the dentition can be performed both by screw-retained and cemented fixed implant prostheses, and with dentures [14].

Full-arch implant rehabilitation, a term used by many doctors, has become a popular restoration option in dental institutions through the use of full-arch screw-retained, cemented fixed, and implant-supported removable prostheses [4,10-12,15,16].

**The purpose of the study** is to study the current treatment level of the oral cavity and to consider a clinical case of rehabilitation of a patient with total edentulism with a full-arch maxillary screw-retained implant supported composite resin prosthesis according to the protocol of immediate loading.

**Materials and methods.** Examination of a person's oral cavity (teeth) begins with a survey, clarification of complaints, medical history, allergic status and medications used by the patient. The survey allows the doctor to establish the correct diagnosis (preliminary). Outline further examination methods (instrumental, laboratory, medical imaging, X-ray, intra-oral X-ray, panoramic X-ray, linear tomography, layered X-ray, computer tomography, magnetic resonance imaging, ultrasound). The methods of system and structural-logical analysis were used. The materials were documents and information sources, legislation and normative, legal acts of Ukraine regarding medical and dental care for the population.

These studies are part of the research works of the Lviv Medical University on the topic "Improving the system of drug circulation during pharmacotherapy on the basis of evidentiary and forensic pharmacy, organization, technology, biopharmacy and pharmaceutical law" (state registration number 0120U105348, implementation period 2021-2026).

### **Results and their discussion.**

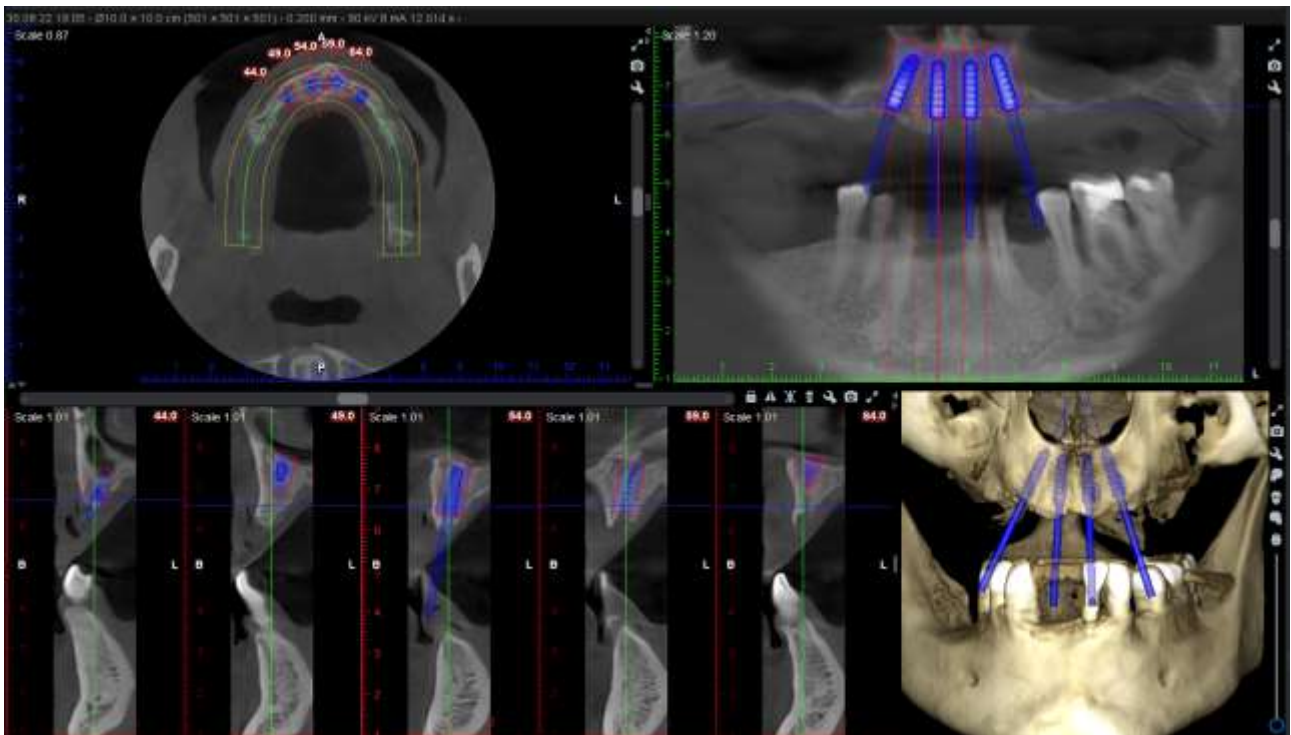
*Clinical case.* A 51-year-old man turned to the doctors of the Lviv health care facility, which provides dental care, for the rehabilitation of a complete dentition of the upper jaw. During the interview with the doctor, it was established that the patient was not a smoker. After examination, no accompanying systemic pathologies were found. The patient complained about the absence of teeth, unsatisfactory aesthetics, poor fixation and stabilization of a nylon denture, impaired chewing function. After a thorough examination and preparation of a treatment plan, it was decided to place 4 implants on the maxilla utilizing a surgical guide over the patient's denture (Fig. 1).

For provisional restoration it was decided to fabricate screw-retained metal-resin implant-supported prosthesis according to the protocol of immediate loading.

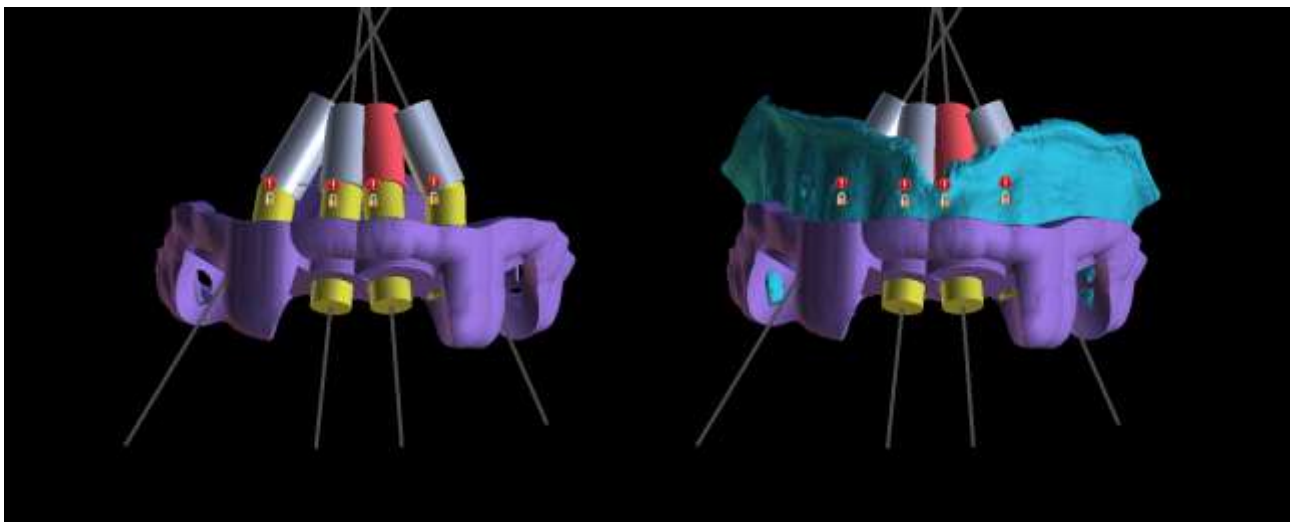
Due to time constraints, the authors decided to make a surgical guide based on the patient's denture, in which holes were cut for implants placement.

The creation of digital models (Fig. 2) of the patient's jaws and prosthesis was carried out using a 3D scanner Aoralscan 3 (Shining 3D Tech Co., Ltd., China). The surgical guide (Fig. 3) was created using BlueSkyPlan software (BlueSkyBio, USA).

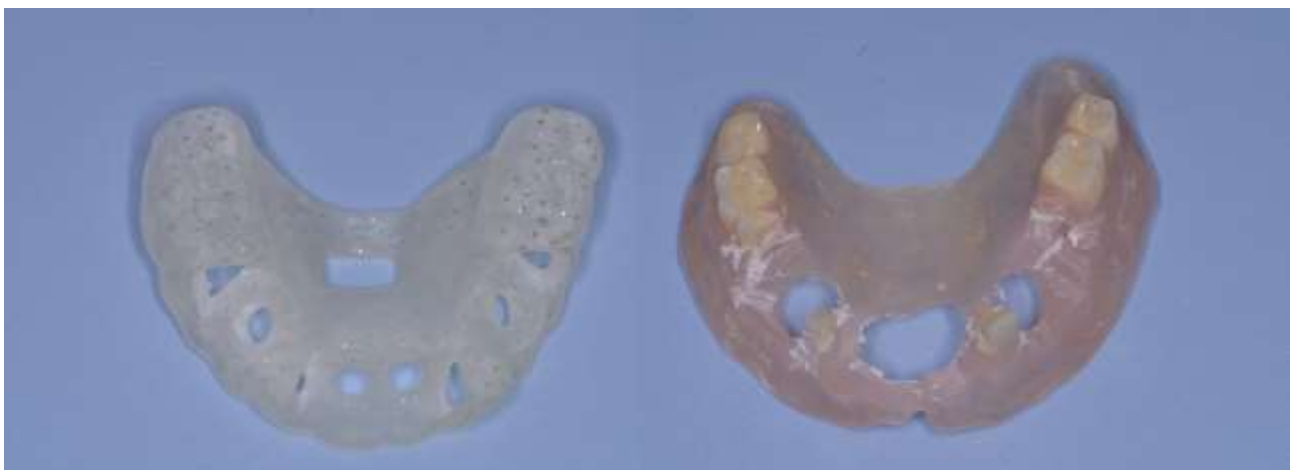
The surgery was performed under local anesthesia with articaine and adrenaline 1:100000 solution (Septanest with adrenaline 1:100.00, SEPTODONT, France).



**Fig. 1.** Patient's CBCT with implants positioning plan.



**Fig. 2.** The surgical guide and denture digital models with planned implants positioning.

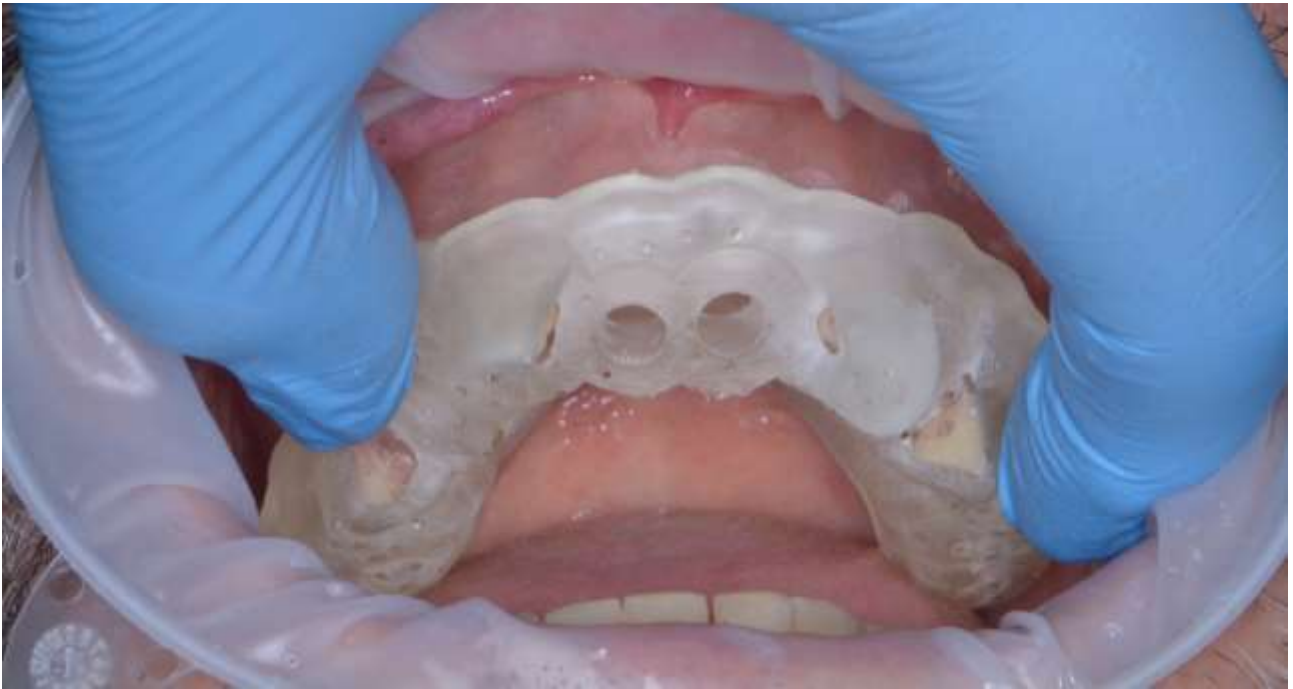

**Fig. 3.** The surgical guide and modified patient's denture.

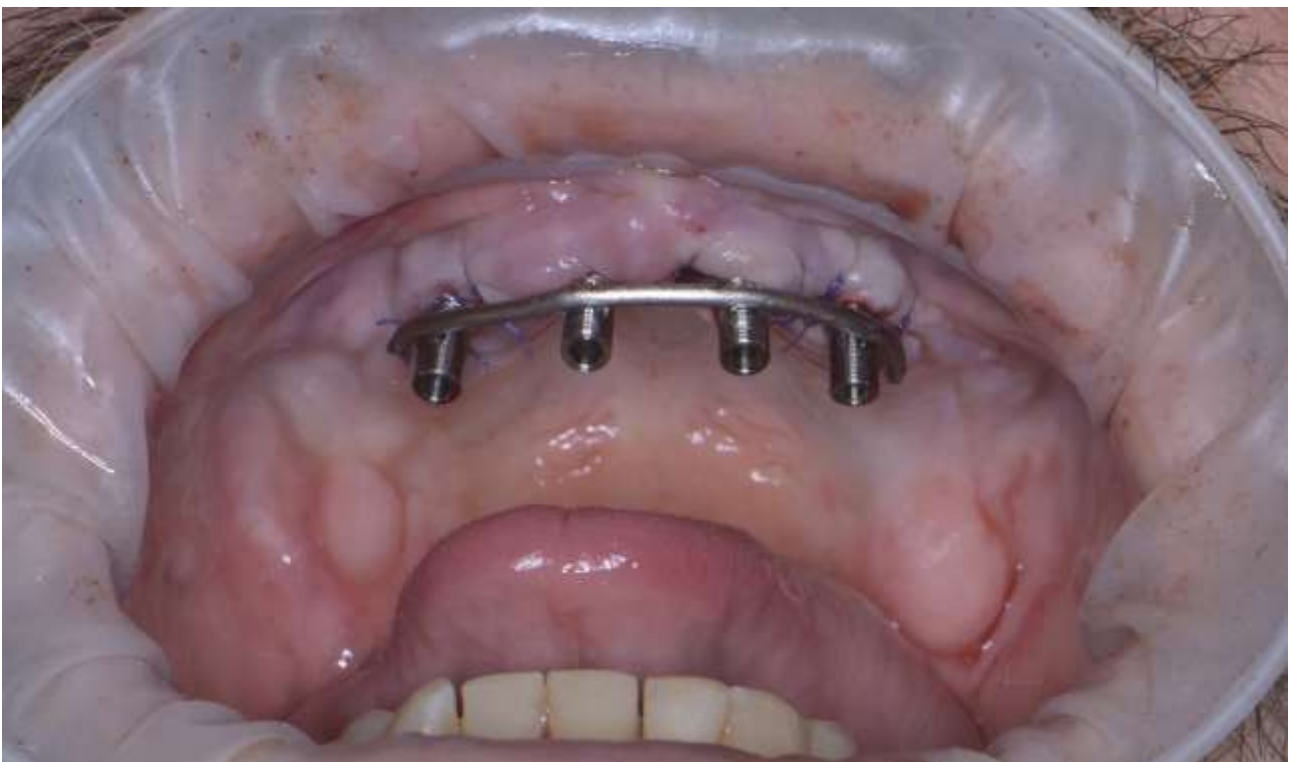First, the patient's denture was fitted with a surgical guide over it (Fig. 4). A total of 4 implants were placed in maxilla in the position of 13, 11, 21, 23 teeth. Cowellmedi Inno Submerged implants, Republic of Korea were used. The dimensions of the implants were 3.5×12 mm (four).

standard surgical procedure using the Cowellmedi Inno Submerged Implant Navigation Drill Set was followed for implant placement. The initial stability of the implants was adequate for immediate loading (45 N/cm, measured with a Saeshin X-cube surgical motor, Republic of Korea) for all implants.

After the surgical part, 4 titanium cylinders splinted by a titanium wire with intraoral welding (Smart IW, Creation Medical solutions, Italy) for temporary restoration were installed in the patient's oral cavity – in this way, the metal frame of the restoration was created (Fig. 5).



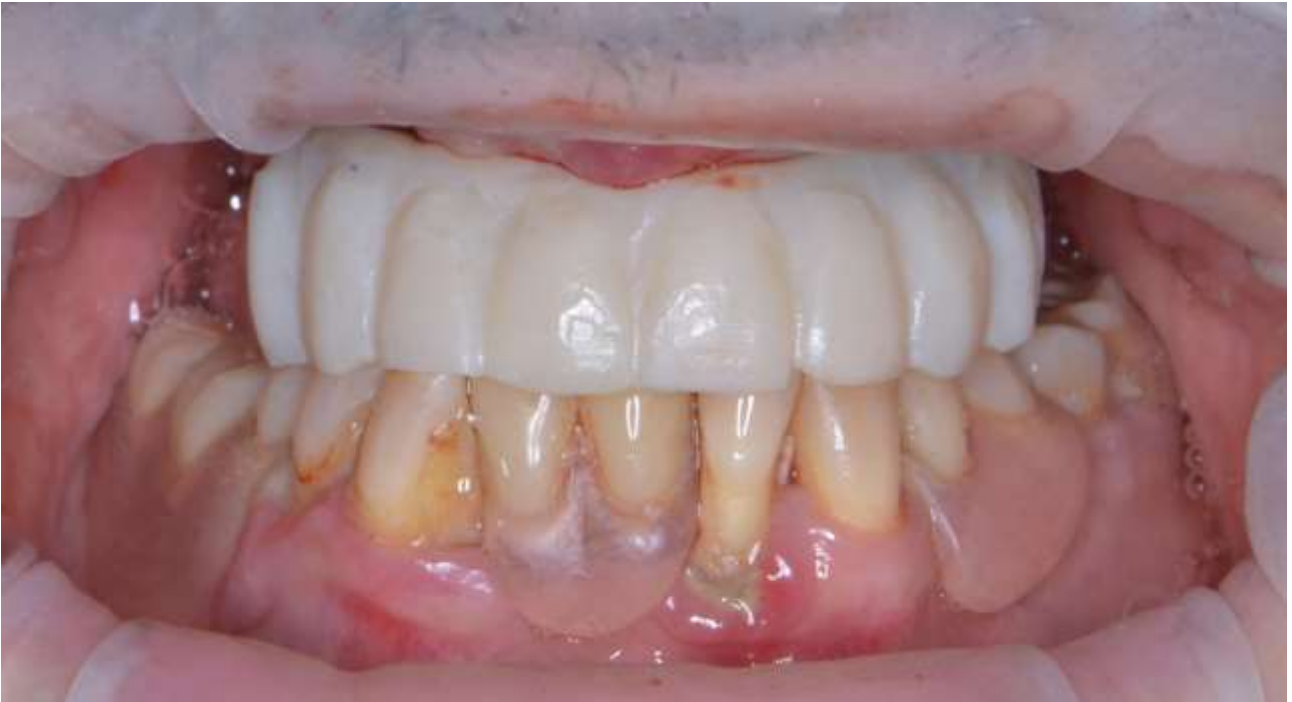**Fig. 4.** Fitting of the modified patient's denture and surgical guide.



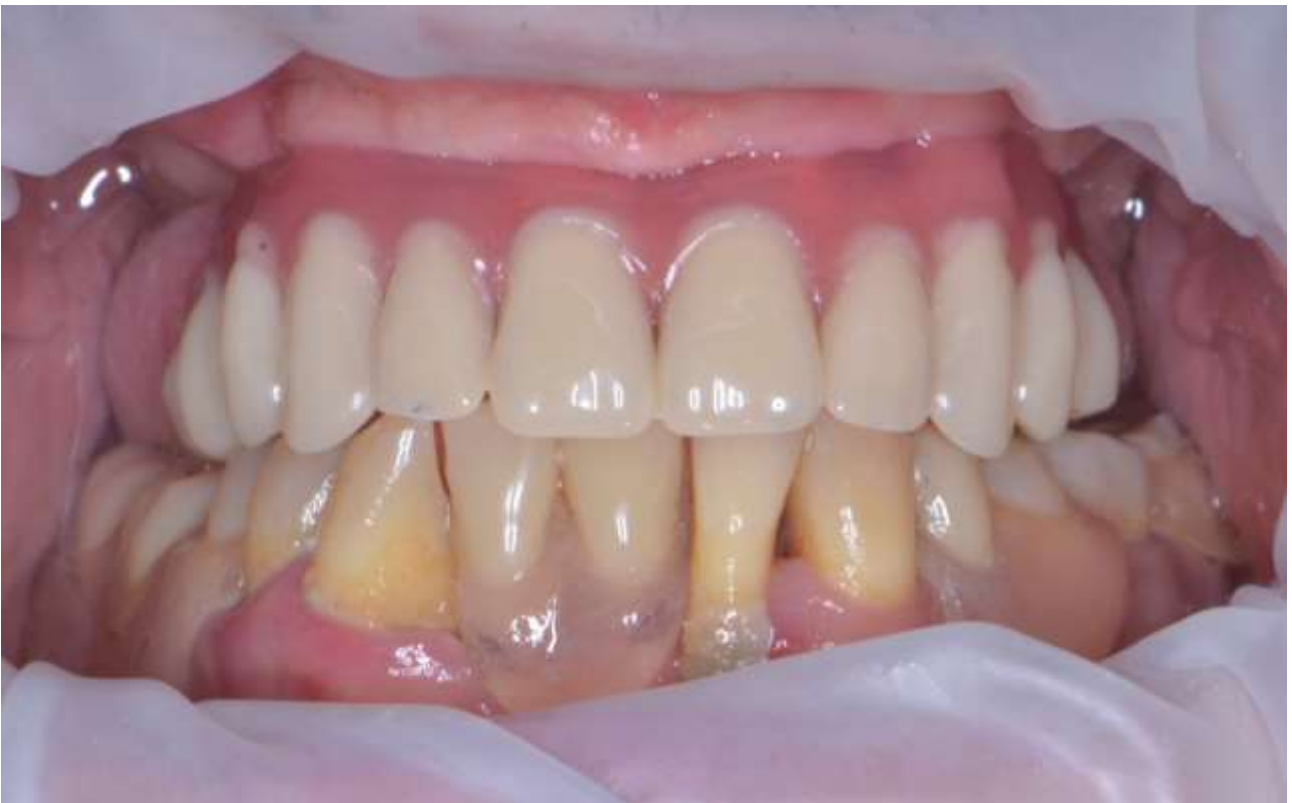**Fig. 5.** The intraorally welded metal frame of the provisional restoration.

The provisional restoration was fabricated by placing a fast-setting composite resin (3M ESPE Protemp 4, Germany) into a silicone impression material template (Oxasil, Kulzer GmbH., Germany) made from the patient's complete removable prosthesis (Fig. 6).

Thus, the patient underwent maxillary anterior implant placement with immediate loading by the screw-retained metal-resin implant-supported prosthesis in one visit.



**Fig. 6.** Direct composite provisional restoration over the metal frame.



**Fig. 7.** The final screw-retained metal-acrylic implant-supported restoration.

After 3 months, according to the standard method, the final screw-retained metal-acrylic implant-supported prosthesis was made, supported by four Cowellmedi Inno Submerged dental implants, taking into account aesthetic and functional requirements, the most important of which were (Fig. 7):

- centric contacts – even distribution occlusal contacts with small and centered over the implants;
- eccentric contacts – anterior guidance only, distributed over multiple teeth;
- angle of tooth contact – shallow as possible to minimize shear forces but still disocclude posterior teeth;
- jaw-to-jaw position – centric relation as defined by Dawson to be able to control tooth contacts. [17].

Implant-supported fixed prosthesis is the best option available to patients for the rehabilitation of edentulous jaws. Immediate loading of a fixed prosthesis significantly improves the quality of life of patients during osseointegration of implants. Marginal bone loss around implants splinted with an immediate loading does not statistically differ from implants installed and loaded according to the standard method [17,18]. In addition, platform switching, the Morse taper implant-abutment connection, and the microstructured texture of the implant surface as demonstrated in the Cowellmedi Inno Submerged implants may have a significant role in the stability of surrounding implant tissues [19-22].

**Conclusions.** Tooth loss is a dangerous process associated with the development of concomitant diseases in accordance with ICD-11 [23].

The main advantage of computer technologies usage in dentistry is extremely high accuracy and speed of manufacturing prostheses. Nowadays there are 19 CAD/CAM systems known, each of which is a high-tech product and is constantly being improved. This contributes to the production of a wide range of prostheses from various materials: titanium, gold alloys, ceramics, resin, composites. Modern systems allow you to mill 14-unit prosthesis frames made of titanium or zirconium dioxide.

The advantages of dental implants over bridge-like and removable dentures include the following improvements in patients:

- ✓ self-esteem, a beautiful and healthy smile returns, which helps to feel more confident, express emotions openly;
- ✓ aesthetics, implants help to completely restore the dentition;
- ✓ phonetics, lack of teeth or ill-fitting dentures can deform pronunciation;
- ✓ restoration of the function of chewing food;
- ✓ comfortable feelings;
- ✓ durability of implants.

The quality of life of each person affects activities, ability to work and its harmonious development. One of the elements related to the quality of life is the level of health of the oral cavity and teeth. Periodontal diseases are among the most common non-infectious diseases. Implant-supported fixed prosthesis is the best option available to patients for the rehabilitation of edentulous jaws. Immediate loading of a fixed prosthesis significantly improves the quality of life of patients during osseointegration period of implants. The use of immediate loading of fixed prostheses has demonstrated clinical efficacy that extends to oral health-related quality of life and patient satisfaction. A successful treatment outcome requires correct diagnostics and accurate implantat planning.

**Conflict of interest.** The authors declare that the study was conducted in the absence of any commercial or financial relationships that could be considered a conflict and/or potential conflict of interest.

**Ethical approval.** The authors of the article certify that the obtained clinical data and research were conducted in compliance with the requirements of moral and ethical principles based on medical and pharmaceutical law. Ethical permission was granted by the administration of the higher private educational institution "Lviv Medical University". During data collection, the main purpose of the study was clearly explained to each department (interested staff) and patients.

**Funding.** The authors state that this research received no specific grant from any funding agency in the public, commercial, or not-for-profit sectors.

### References.

1. WHO. Oral health. (2023). URL: <https://www.who.int/news-room/fact-sheets/detail/oral-health>
2. Tonetti, M. S., Greenwell, H., & Kornman, K. S. (2018). Staging and grading of periodontitis: Framework and proposal of a new classification and case definition. *Journal of periodontology*, 89 Suppl 1, S159–S172. DOI: <https://doi.org/10.1002/JPER.18-0006>
3. Nocini R., Lippi G., Mattiuzzi C. (2020). Periodontal disease: the portrait of an epidemic. *JPHE*. No.4:10. DOI: 10.21037/jphe.2020.03.01
4. Shchepanskyi B. Modern dental medical care: complete rehabilitation of the upper jaw with support on implants. *Actual Problems of Medicine and Pharmacy*. 2023. Vol. 4. No.1. P.1-13. doi: <https://doi.org/10.52914/apmp.v4i1.53>
5. Pelehan, B.L., Rozhko, M.M., & Pelehan, L.I. (2021). Prevalence of the need for the prosthodontic treatment of edentulousness in the residents of ivano-frankivsk region in the period of 2016–2020. *Visnyk stomatologii*, 115(2), 78-84. DOI: <https://doi.org/10.35220/2078-8916-2021-40-2.15>
6. Ewoldsen N. (2011). Complete denture services: clinical technique, lab costs, manpower, and reimbursement. One-year review. *Journal (Indiana Dental Association)*, 90(2), 12–15.
7. Pietrovovski, J., Kaffe, I., & Arensburg, B. (2007). Retromolar ridge in edentulous patients: clinical considerations. *Journal of prosthodontics: official journal of the American College of Prosthodontists*, 16(6), 502–506. DOI: <https://doi.org/10.1111/j.1532-849X.2007.00225.x>
8. Lang, N. P., Müller, F., & Working Group I (2007). Epidemiology and oral function associated with tooth loss and prosthetic dental restorations. Consensus report of Working Group I. *Clinical oral implants research*, 18 Suppl 3, 46–49. DOI: <https://doi.org/10.1111/j.1600-0501.2007.01437.x>
9. Cercadillo-Ibarguren, I., Sánchez-Torres, A., Figueiredo, R., & Valmaseda-Castellón, E. (2017). Bimaxillary simultaneous immediate loading of full-arch restorations: A case series. *Journal of clinical and experimental dentistry*, 9(9), e1147–e1152. DOI: <https://doi.org/10.4317/jced.54172>
10. Mello, C. C., Lemos, C. A. A., Verri, F. R., Dos Santos, D. M., Goiato, M. C., & Pellizzer, E. P. (2017). Immediate implant placement into fresh extraction sockets versus delayed implants into healed sockets: A systematic review and meta-analysis. *International journal of oral and maxillofacial surgery*, 46(9), 1162–1177. DOI: <https://doi.org/10.1016/j.ijom.2017.03.016>
11. Menéndez-Collar, M., Serrera-Figallo, M. A., Hita-Iglesias, P., Castillo-Oyagüe, R., Casar-Espinosa, J. C., Gutiérrez-Corrales, A., Gutiérrez-Perez, J. L., & Torres-Lagares, D. (2018). Straight and tilted implants for supporting screw-retained full-arch dental prostheses in atrophic maxillae: A 2-year prospective study. *Medicina oral, patologia oral y cirugía bucal*, 23(6), e733–e741. DOI: <https://doi.org/10.4317/medoral.22459>
12. Slutzkey, G. S., Cohen, O., Chaushu, L., Rahmanov, A., Mijiritsky, E., Beitlitum, I., & Kolerman, R. (2022). Immediate Maxillary Full-Arch Rehabilitation of Periodontal Patients with Terminal Dentition Using Tilted Implants and Bone Augmentation: A 5-Year Retrospective Cohort Study. *Journal of clinical medicine*, 11(10), 2902. DOI: <https://doi.org/10.3390/jcm11102902>
13. Cerea, M., & Dolcini, G. A. (2018). Custom-Made Direct Metal Laser Sintering Titanium Subperiosteal Implants: A Retrospective Clinical Study on 70 Patients. *BioMed research international*, 2018, 5420391. DOI: <https://doi.org/10.1155/2018/5420391>
14. Gargari, M., Prete, V., Pujia, A., & Ceruso, F. M. (2013). Full-arch maxillary rehabilitation fixed on 6 implants. *ORAL & implantology*, 6(1), 1–4.
15. Caramês, J. M. M., Marques, D. N. D. S., Caramês, G. B., Francisco, H. C. O., & Vieira, F. A. (2021). Implant Survival in Immediately Loaded Full-Arch Rehabilitations Following an Anatomical Classification System-A Retrospective Study in 1200 Edentulous Jaws. *Journal of clinical medicine*, 10(21), 5167. DOI: <https://doi.org/10.3390/jcm10215167>

16. Carossa, M., Alovisi, M., Crupi, A., Ambrogio, G., & Pera, F. (2022). Full-Arch Rehabilitation Using Trans-Mucosal Tissue-Level Implants with and without Implant-Abutment Units: A Case Report. *Dentistry journal*, 10(7), 116. DOI: <https://doi.org/10.3390/dj10070116>
17. Dawson P. (1989) *Evaluation, diagnosis and treatment of occlusal problems*. 2nd ed. St. Louis: CV Mosby. P. 28–55.
18. Esposito, M., Felice, P., Barausse, C., Pistilli, R., Grandi, G., & Simion, M. (2015). Immediately loaded machined versus rough surface dental implants in edentulous jaws: One-year postloading results of a pilot randomised controlled trial. *European journal of oral implantology*, 8(4), 387–396. URL: <https://pubmed.ncbi.nlm.nih.gov/26669548/>
19. Gonzalez-Gonzalez, I., deLlanos-Lanchares, H., Brizuela-Velasco, A., Alvarez-Riesgo, J. A., Llorente-Pendas, S., Herrero-Climent, M., & Alvarez-Arenal, A. (2020). Complications of Fixed Full-Arch Implant-Supported Metal-Ceramic Protheses. *International journal of environmental research and public health*, 17(12), 4250. DOI: <https://doi.org/10.3390/ijerph17124250>
20. Lazzara, R. J., & Porter, S. S. (2006). Platform switching: a new concept in implant dentistry for controlling postrestorative crestal bone levels. *The International journal of periodontics & restorative dentistry*, 26(1), 9–17. URL: <https://pubmed.ncbi.nlm.nih.gov/16515092/>
21. Peñarrocha-Oltra, D., Covani, U., Peñarrocha-Diago, M., & Peñarrocha-Diago, M. (2014). Immediate loading with fixed full-arch protheses in the maxilla: review of the literature. *Medicina oral, patologia oral y cirugia bucal*, 19(5), e512–e517. DOI: <https://doi.org/10.4317/medoral.19664>
22. Pesce, P., Menini, M., Tommasato, G., Patini, R., & Canullo, L. (2019). Influence of modified titanium abutment surface on peri-implant soft tissue behaviour: A systematic review of histological findings. *International journal of oral implantology (Berlin, Germany)*, 12(4), 419–429. URL: <https://pubmed.ncbi.nlm.nih.gov/31781697/>
23. Shapovalova, V. (2022). The ICD-11 for the twenty-first century: the first view from the organizational, legal, clinical and pharmacological aspects. *SSP Modern Pharmacy and Medicine*, 2(1), 1-13. <https://doi.org/10.53933/sspm.v2i1.37>